

## Cutaneous T-Cell Lymphoma after Polycythemia Vera: An Iranian Case Report

Mazaher Ramezani<sup>1</sup>, Elias Salimi<sup>2</sup>, Masoud Sadeghi<sup>3\*</sup>

<sup>1</sup>Department of Pathology, School of Medicine, Kermanshah University of Medical Sciences, Kermanshah, Iran

<sup>2</sup>Department of Dermatology, School of Medicine, Kermanshah University of Medical Sciences, Kermanshah, Iran

<sup>3</sup>Medical Biology Research Center, Kermanshah University of Medical Sciences, Kermanshah, Iran

### \*Corresponding author

Masoud Sadeghi

Email: [sadeghi\\_mbrc@yahoo.com](mailto:sadeghi_mbrc@yahoo.com)

**Abstract:** Concomitant polycythemia vera (PV) and primary cutaneous T-cell lymphomas (CTCL) is very rare. In this report, we describe a patient who developed CTCL after PV, receiving long-term hydroxyurea for PV. The patient referred with large Erythematous patches and plaques on back, flanks and legs. The pathology report showed CTCL. Also, the case had had PV since twenty years ago with phlebotomy as the treatment at the first and under treatment with hydroxyurea since thirteen years ago. In conclusion, the present case and other studies suggest that during treatment of PV any unidentified lesions should be carefully considered to exclude the possibility of a second haematopoietic neoplasm. Also, our case provides further evidence of the potential tumorigenic effects of long-term follow-up hydroxyurea.

**Keywords:** Cutaneous T-cell lymphoma, Polycythemia vera, Case report.

### INTRODUCTION

Polycythemia vera (PV) is a chronic myeloproliferative disorder characterized by increased red blood cell mass. The resultant hyperviscosity of the blood predisposes such patients to thrombosis. Polycythemia vera should be suspected in patients with elevated hemoglobin or hematocrit levels, splenomegaly, or portal venous thrombosis[1]. Hydroxyurea, a nonalkylating myelosuppressive agent, is now widely used in PV treatment [2]. Primary cutaneous T-cell lymphomas (CTCLs), which include mycosis fungoides and Sezary syndrome, encompass a clinically and biologically heterogeneous group of non-Hodgkin lymphomas (NHLs) defined by clonal proliferation of skin-homing malignant T lymphocytes and natural killer cells that account for up to 75%- 80% of all cutaneous lymphomas [3].CTCLs encompass a wide variety of lymphomas that are characterized by the localization of the malignant lymphocytes to the skin at presentation. Advances in molecular biologic techniques, including immunophenotyping and gene rearrangement studies to determine clonality, have led to more frequent diagnosis of CTCL as well as more consistent subclassification of these entities [4].

In this report, we describe a patient who developed CTCL after PV, receiving long-term hydroxyurea for PV.

### CASE REPORT

A 75-year-old man referred to a Dermatologist on January 2016, with large Erythematous patches and

plaques on back, flanks and legs (Figure 1A and Figure 1B). The patient had had Erythematous plaques since four years ago. A biopsy was taken and sent to Dermatopathology Center. Clinical impressions were Mycosis Fungoides, Drug reaction, Well's syndrome and Erythema annulare *centrifugum*. The pathology report showed CTCL (Mycosis Fungoides, plaque stage) (Figure 2). Also, the case had had PV since twenty years ago with phlebotomy (twice monthly) as the treatment at the first and under treatment with hydroxyurea since thirteen years ago. ASA, Diclofenac, Losartan, C-Lax and Allopurinol have been used rather regularly in his drug history. He is now alive on April 2016.

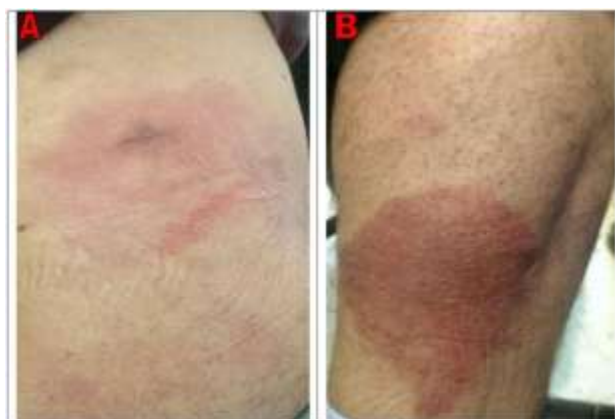


Fig-1: Erythematous patches and plaques on: (A) flank, (B) leg

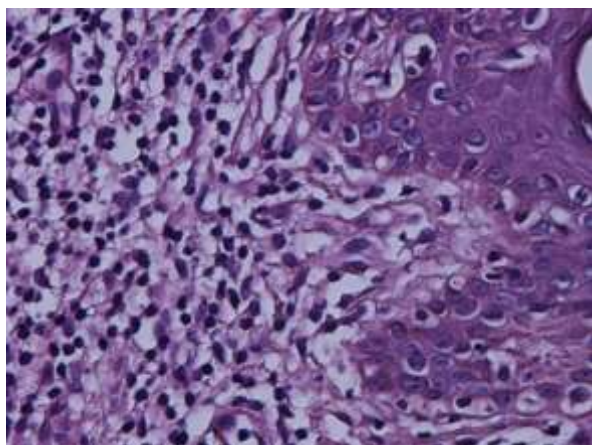


Fig-2: Mycosis Fungoides, H&E staining (×400)

## DISCUSSION

The association of myeloproliferative and lymphoproliferative disorders is well known after cytotoxic drug or radiation exposure, while it is remarkably rare prior to therapy [5]. Cottrill *et al.* [6] reported a patient with PV and CTCL in 1994 that based on our knowledge, it is just reported case similar to our case that CTCL was developed after one year of diagnosis of PV, but in our case after sixteen years of diagnosis of PV. In a study on 682 cases of PV, the risk of developing a second neoplasm of the hemopoietic type after 10 years of follow-up was 10% in patients treated with  $^{32}\text{P}$ , 10% in those treated with non-radiomimetic agents (hydroxyurea or pipobroman), and 19% if, after  $^{32}\text{P}$ , hydroxyurea had been used [7]. The simultaneous or sequential occurrence of polycythemia vera (PV) and a chronic lymphoproliferative disorder in previously untreated patients involved chronic lymphocyticleukaemia, multiple myeloma or lymphoma [5]. The association of lymphoproliferative disorders and polycythemia vera (PV) is extremely rare [8]. NHLs may arise in association with other haematological neoplastic conditions but they are rarely associated with PV [9,10]. Many of these neoplasms are the consequence of using alkylating agents such as hydroxyurea or chlorambucil or radioisotopes such as  $^{32}\text{P}$  to treat PV [10]. Ellis *et al.* [9] reported that large-cell lymphocytic lymphoma created at least 5 years after the diagnosis of PV in five patients treated with chlorambucil. Schlaifer *et al.* [11] reported two cases of NHL in patients treated with  $^{32}\text{P}$  for PV. On the contrary, Steinberg *et al.* [8] reported the case of a PV patient with an abdominal NHL that had been treated with only a short cycle of bisulphane. Hawkins *et al.* [2] reported a case with PV that developed lymphoma and concluded treatment with hydroxyurea may be a contributing factor in the development of lymphoma.

## CONCLUSIONS

The present case and other studies suggest that during treatment of PV any unidentified lesions should be carefully considered to exclude the possibility of a second haematopoietic neoplasm. Also, our case

provides further evidence of the potential tumorigenic effects of long-term follow-up hydroxyurea.

## REFERENCES

1. Stuart BJ, Viera AJ; Polycythemia vera. *Am Fam Physician.*, 2004; 69(9):2139-44.
2. Hawkins TE, Carter JM, Romeril KR, Jackson SR, Green GJ; Lymphoma transformation in polycythaemia vera treated with hydroxyurea. *Am J Hematol.*, 1993;44(4):290.
3. Rosen ST, Querfeld C; Primary cutaneous T-cell lymphomas. *Hematology Am Soc Hematol Educ Program.*, 2006; 323-30, 513.
4. Siegel RS, Pandolfino T, Guitart J, Rosen S, Kuzel TM; Primary cutaneous T-cell lymphoma: review and current concepts. *J Clin Oncol.*, 2000;18(15):2908-25.
5. Rizzi R, Liso A, Pannunzio A, Carluccio P, Specchia G, Liso V; Concomitant primary polycythemia vera and follicle center cell non-Hodgkin lymphoma: a case report and review of the literature. *Leuk Lymphoma*, 2002; 43(11):2217-20.
6. Cottrill C, Geller A, diSpaltro FX, Weissglass B, Klainer AS, Bisaccia E; Control of polycythaemia vera with photochemotherapy in a patient with cutaneous T-cell lymphoma. *Br J Haematol.*, 1994;86(1):225-6.
7. Najean Y, Rain JD, Dresch C, Goguel A, Lejeune F, Echard M, Grange MJ; Risk of leukaemia, carcinoma, and myelofibrosis in  $^{32}\text{P}$ -or chemotherapy-treated patients with polycythaemia vera: a prospective analysis of 682 cases. *Leukemia & lymphoma*, 1996; 22(sup1):111-9.
8. Steinberg E, Ben-Dor D, Lugassy G; Anaplastic B-cell (Ki-1) lymphoma developing in a patient with polycythemia vera. *Leuk Lymphoma*, 1995; 19(5-6):507-9.
9. Ellis JT, Peterson P, Geller SA, Rappaport H; Studies of the bone marrow in polycythemia vera and the evolution of myelofibrosis and second hematologic malignancies. *Seminars in Hematology*, 1986; 23(2):144-55.
10. Castellano S, Carbone M, Carozzo M, Broccoletti R, Pagano M, Vasino MA, Gandolfo S; Onset of oral extranodal large B-cell non-Hodgkin's lymphoma in a patient with polycythemia vera: a rare presentation. *Oral oncology*, 2002; 38(6):624-6.
11. Schlaifer D, Dastugue N, Brousset P, Delsol G, Muller C, Rigal-Huguet F, Attal M, Laurent G, Pris J; B-cell lymphoma following polycythemia vera: evidence for the involvement of two different clones. *Leukemia*, 1994; 8(5):895-6.