

Unilateral Blindness in a Patient with Subarachnoid Hemorrhage after Rupture of Anterior Communicating Artery Aneurysm

Shinji Makino

Department of Ophthalmology, Jichi Medical University, Shimotsuke, Tochigi, Japan

*Corresponding author

Shinji Makino

Email: makichan@jichi.ac.jp

Abstract: We present a case of unilateral blindness with subarachnoid hemorrhage after rupture of an anterior communicating artery aneurysm. Her corrected visual acuity was 1.2 in the right eye and no light perception in the left eye. Fundus examination revealed intrarerinal and subretinal hemorrhages and optic disc atrophy in the left eye. We speculated the condition as an ischemic optic neuropathy. Although the retinal hemorrhages were gradually reduced, her left visual acuity was still no light perception. We should be aware of the potential for subarachnoid hemorrhage resulting in optic nerve damage and retinal hemorrhage.

Keywords: Subarachnoid hemorrhage, Ischemic optic neuropathy.

INTRODUCTION

Vitreous hemorrhage in association with subarachnoid hemorrhage (SAH) is termed “Terson syndrome”, yet other forms of posterior segment hemorrhages are known to occur with intracranial bleeding [1]. Many authors have considered all types of intraocular hemorrhage to be Terson syndrome, although each may have a different prognosis [1, 2]. Generally, the visual outcome after SAH from aneurysm rupture seems to be better [1].

Several reports have described visual acuity in patients with SAH, but reports describing total blindness are extremely rare [3, 4]. Furthermore, reports describing optic disc atrophy following SAH are extremely rare [5]. Hara *et al.* [5] described that two cases with visual field defects and optic disc atrophy associated with SAH following a rupture of an anterior communicating artery aneurysm.

Herein, we report a case of unilateral blindness with SAH after rupture of an anterior communicating artery aneurysm.

CASE REPORT

A 51-year-old woman was referred with decreased visual acuity in the left eye when she recovered from disturbance of consciousness caused by SAH that had occurred 1 month earlier as a result of rupture of an aneurysm of the anterior communicating artery. Before the SAH, she had noticed no visual problem in either eye. On the first examination, the corrected visual acuity was 1.2 in the right eye and no light perception in the left eye. Slit lamp examination did not reveal abnormalities in either anterior segment. On fundus examination, intrarerinal, subretinal hemorrhages and optic disc atrophy were more clearly detected in the left eye (Figure 1).

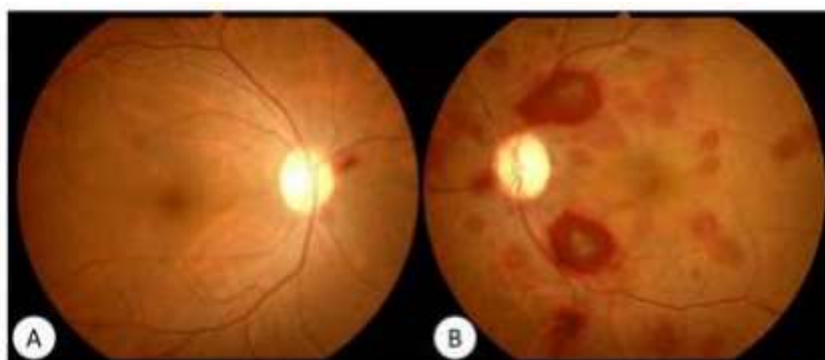


Fig-1: Fundus photographs of the right (A) and left (B) eye at the initial visit

Note multiple retinal hemorrhages in different sizes and shapes scattered over the posterior pole.

We speculated the condition as an ischemic optic neuropathy. Although the retinal hemorrhages were gradually reduced, her left visual acuity was still no light perception.

DISCUSSION

Entezari *et al.* [2] evaluated the fundus findings in 202 eyes of 101 patients with SAH. According to their report, 50 (49.5%) patients had normal and 51 (50.5%) patients had abnormal funduscopic examination. Of all eyes, disc swelling in 85 (42.1%), retinal hemorrhage in 51 (25.2%), subhyaloid hemorrhage in 6 (3%), and vitreous hemorrhage in 3 (1.5%) eyes were detected. Stiebel-Kalish *et al.* [1] reported the natural history of SAH-related intraocular hemorrhages. According to their report, visual acuity at presentation varied with the degree of macular involvement or blockage by the intraocular blood. In the vitreous hemorrhage subgroup, visual acuity ranged from 20/100 to light perception. Visual acuity ranged from 20/20 to 20/400 in the predominantly subhyaloid blood group. Patients with retinal hemorrhages alone had a visual acuity ranging from 20/20 to 20/40. In addition, they describe that the visual outcome after SAH from aneurysm rupture seems to be generally better and no eyes had concurrent optic neuropathy.

However, this present case demonstrated unilateral blindness with SAH after rupture of an anterior communicating artery aneurysm. A case of total blindness following rupture of an anterior communicating artery aneurysm associated with a documented period of reduction in global cerebral blood flow has been reported [3]. Hara *et al.* [5] described two cases with optic disc atrophy due to ischemic optic neuropathy following rupture of an anterior communicating artery aneurysm.

The intensity of SAH is an important risk factor for cerebral vasospasms, particularly when a thick hematoma is located in the subarachnoid space [5]. This suggests that ischemia at the optic chiasm and optic nerve is affected by cerebral vasospasms after SAH [5]. Clinicopathologically, Ko *et al.* [6] described that hemorrhage of the optic nerve sheath was a frequent complication of SAH. It occurred within the dural sheath, subdural space, subarachnoid space, or pia mater.

Although we could not examine this present case at the initial phase of SAH, we speculated the condition as an ischemic optic neuropathy.

Finally, clinicians should be aware of the potential for SAH resulting in optic nerve damage and retinal hemorrhage.

REFERENCES

1. Stiebel-Kalish H, Turtel LS, Kupersmith MJ. The natural history of nontraumatic subarachnoid hemorrhage-related intraocular hemorrhages. *Retina*. 2004;24(1): 36-40.
2. Entezari M, Azhari S, Ramezani A. Fundus findings in spontaneous subarachnoid hemorrhage and their correlation with neurologic characteristics. *Eur J Ophthalmol*. 2009;19(3):460-465.
3. Ruben S, Afshar F. Visual failure following subarachnoid haemorrhage from rupture of an anterior communicating artery aneurysm. *J Neurol Neurosurg Psychiatry*. 1991;54(11):1017-1018.
4. Thygesen J, Rosenørn J. Transient bilateral blindness in relation to subarachnoid haemorrhage caused by spastic ischaemic changes in retina and optic nerve. *Acta Ophthalmol (Copenh)*. 1982;60(2):325-331.
5. Hara N, Mukuno K, Ohtaka H, Shimizu K. Ischemic optic neuropathy associated with subarachnoid hemorrhage after rupture of anterior communicating artery aneurysm. *Ophthalmologica*. 2003;217(1):79-84.
6. Ko F, Knox DL. The ocular pathology of Terson's syndrome. *Ophthalmology*. 2010;117(7):1423-1429.e2.