

Nodular Lymphoid Hyperplasia of Small Intestine: A Case Report

Dr. Bijayalaxmi Sahoo, Dr. Hemalatha Ganapathy, Dr. B.O Parijatham

Department of Pathology, Sree Balaji Medical College And Hospital, Chennai, Tamil Nadu, India

***Corresponding author**

Dr. Bijayalaxmi Sahoo

Email: bijayalaxmi_sahoo@outlook.com

Abstract: Nodular lymphoid hyperplasia (NLH) of the gastrointestinal tract is characterized by the presence of multiple small nodules, between 2 and 10 mm in diameter. Although it may be detected in the stomach, large intestine or rectum, it is more often distributed in the small intestine. The pathogenesis is largely unknown. The present article shows a case report of Nodular Lymphoid Hyperplasia of small Intestine.

Keywords: Nodular Lymphoid Hyperplasia, Small Intestine.

INTRODUCTION

Nodular lymphoid hyperplasia of the gastrointestinal tract is a rare disorder and is characterized by the presence of multiple small nodules, normally between 2 and 10 mm in diameter, distributed along the small intestine (more often), stomach, large intestine, or rectum. It can occur in all age groups and can affect people with or without immunodeficiency [1]. Histologically, NLH is defined by markedly hyperplastic, mitotically active germinal centers, and well defined lymphocyte mantles found in the lamina propria and/or in the superficial submucosa. There are two forms of focal lymphoid hyperplasia are seen in the distal small intestine:

- The first, seen in very young patients, is rare and presents as a tumour-like appearance in the terminal ileum.
- The second, focal hyperplasia in the terminal ileum, also rare, occurs most commonly in older individuals.

The present article shows a case report of Nodular Lymphoid Hyperplasia of small Intestine in a 25 year old female patient presenting with complaints of Vomiting.

CASE REPORT

A 25 year female patient came to the Department of General Surgery, presenting with complaints of vomiting, End to End ileocolic anastomosis was done. The specimen with mesenteric lymph nodes was sent for histopathological examination.

Grossly, small intestine with caecum, appendix in to measuring 60cm, appendix measuring 5cm. The small intestine appeared to be dilated with a stricture present 5cm from the ileocaecal junction. Cut section at the region of stricture shows multiple ulcerations with

small nodules all over the mucosa. In Histopathological Examination the proximal resected margin showed small intestinal mucosa with ulceration, focal erosion with congestion, edema, dense inflammatory cell collections in the lamina propria. The Distal resected margin showed hypertrophied lymphoid follicles in the lamina propria and submucosa. The Ulcerated area showed ulceration and congestion of mucosa with submucosal edema and fragmented muscle layer. The Stricture showed hyperplastic small intestinal mucosa with increased inflammatory infiltrates in the lamina propria. The polypoidal lesion showed hypertrophied lymphoid follicles with germinal centers in the mucosa.

Appendix showed features of subacute appendicitis with hypertrophied lymphoid follicles. Sections from 15 lymph node studied showed reactive lymphoid hyperplasia with germinal centers dilated and congested sinusoids with focal histiocytic proliferation. There was no evidence of granuloma in any of the sections studied. The final diagnosis was given as Nodular Lymphoid Hyperplasia of Small Intestine with focal ulceration.

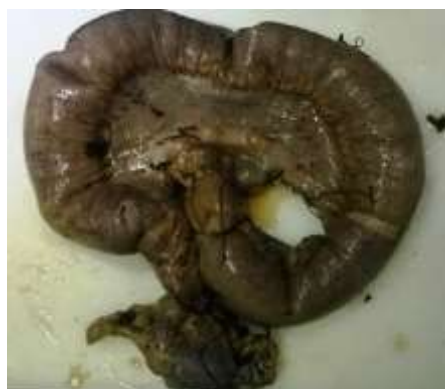

Fig-1: Gross: small intestine with caecum and appendix



Fig-2: Cut section: multiple ulcerations with small nodules

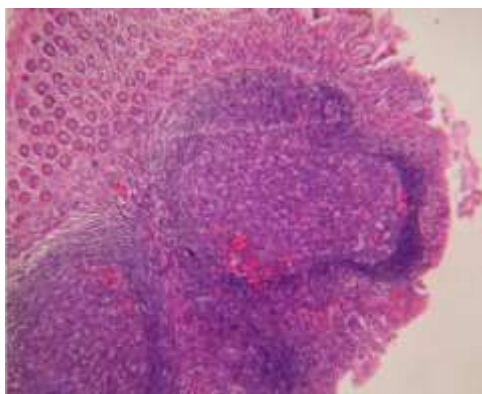


Fig-3: Section showing Hypertrophied lymphoid follicles(Low power view)

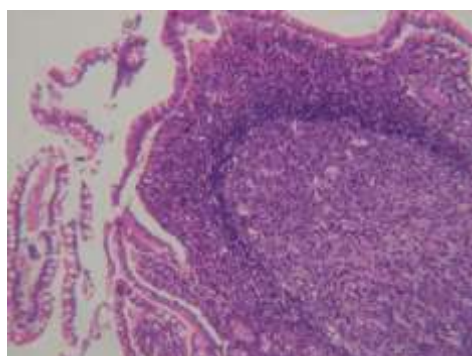


Fig-4: Section showing Small intestinal mucosa with hypertrophied lymphoid follicle showing the germinal centre. (Low power View)

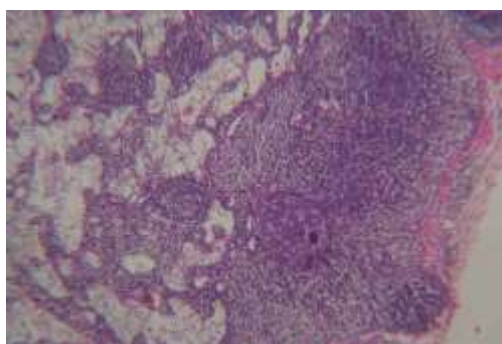


Fig-5: Section showing Cystic dilatation

DISCUSSION

Nodular lymphoid hyperplasia is a lymphoproliferative disease that still remains unknown. The occurrence of nodular lymphoid hyperplasia is rare. It has been reported that about 20% of patients with common variable immunodeficiency syndrome [2-9]. In some cases it was found to be associated with intestinal lymphoma. NLH was also reported in adult patient without any kind of immunodeficiency [10-15]. Few cases were found to have *Giardia Lamblia* infection [15]. There is a theory of the local immune response to the antigens as a stimulators in GI tract, but still no antigen is defined. Nodular lymphoid hyperplasia always needs a differential diagnosis from the other polyposis conditions, especially malignant lymphoma and familial adenomatous polyposis. The most often localisation of hyperplastic lymphoid nodules usually described as innumerable polypoid lesions, is the small bowel, especially the terminal ileum, but they can occur in the stomach and in the colon as well. Rarely, the polypoid lesions themselves can cause bleeding or intestinal obstruction.

CONCLUSION

In conclusion, Nodular Lymphoid Hyperplasia is a rare but problematic disease with respect to diagnosis and treatment. However, it must be distinguished from a variety of polyposis syndromes to avoid misdiagnosis and unnecessary radical treatments.

REFERENCES

1. Albuquerque A. Nodular lymphoid hyperplasia in the gastrointestinal tract in adult patients: A review. *World J Gastrointest Endosc.* 2014;6(11):534-540
2. Bastlein C, Burlefinger R, Holzberg E, Voeth C, Garbrecht M, Ottenjann R. Common variable immunodeficiency syndrome and nodular lymphoid hyperplasia in the small intestine. *Endoscopy.* 1988;20:272-5.
3. Webster AD, Kenwright S, Ballard J, Shiner M, Slavin G, Levi AJ. Nodular lymphoid hyperplasia of the bowel in primary hypogammaglobulinemia: study of in vivo and in vitro lymphocyte function. *Gut.* 1977;18:364-72.
4. Bennett WG, Watson RA, Heard JK, Vesely DL. Home hyperalimentation for common variable hypogammaglobulinemia with malabsorption secondary to intestinal nodular lymphoid hyperplasia. *AmJ Gastroenterol.* 1987;82:1091-5.
5. Laszewski MJ, Kemp JD, Goeken JA, Mitros FA, Plaz CE, Dick FR. Clonal immunoglobulin gene rearrangement in nodular lymphoid hyperplasia of the gastrointestinal tract associated with common variable immunodeficiency. *Am J Clin Pathol.* 1990;94:338-43.
6. Tytgat GN, Huibregtse K, Schellekens PTA, Feltkamp-Vroom TH. Clinical and immunologic observations in a patient with late onset

- immunodeficiency *Gastroenterology*, 1979; 76: 1458-65.
7. Van den Brande P, Geboes K, Vantrappen G, Van den Eeckhout A, Vertessen S, Stevens EA. Intestinal nodular lymphoid hyperplasia in patients with common variable immunodeficiency: local accumulation of B and CD8(+) lymphocytes. *J Clin Immunol*. 1988;8:296-306.
 8. de Weerth, Gocht A, Seewald S, Brand B, van Lunzen, Seitz U. Duodenal nodular lymphoid hyperplasia caused by giardiasis infection in a patient who is immunodeficient. *Gastrointest Endosc*. 2002;55:605-7.
 9. Matuchansky C, Touchard G, Lemaire M, Babin P, Demeocq F, Fonck Y, et al. Malignant lymphoma of the small bowel associated with diffuse nodular lymphoid hyperplasia. *N Engl J Med*. 1985;313:166-71.
 10. Aguilar FP, Alfonso V, Rivas S, Lopez Aldeguer J, Portilla J, Berenguer J. Jejunal malignant lymphoma in a patient with adult-onset hypoglobulinemia and nodular lymphoid hyperplasia of the small bowel. *Am J Gastroenterol*. 1987; 82:472-5.
 11. Cammoun M, Jaafoura H, Tabbane F, Halphen M. Immunoproliferative small intestinal disease without a-chain disease: a pathological study. *Gastroenterology*. 1989;96:750-63.
 12. Castellano G, Moreno D, Galvao O, Ballestin C, Colina F, Mollejo M. Malignant lymphoma of jejunum with common variable hypogammaglobulinemia and diffuse nodular hyperplasia of the small intestine. A case study and literature review. *J Clin Gastroenterol*. 1992; 15:128-35
 13. Rambaud JC, de Saint-Louvent P, Marti R, Galian A, Mason DY, Wassef M. Diffuse follicular lymphoid hyperplasia of the small intestine without primary immunoglobulin deficiency. *Am J Med*. 1982;73:125-32.
 14. Tomita S, Kojima M, Imura J, Ueda Y, Koitabasi A, Suzuki Y. Diffuse nodular lymphoid hyperplasia of the large bowel without hypogammaglobulinemia or malabsorption syndrome: a case report and literature review. *Int J Surg Pathol*. 2002; 10:297-302.
 15. Ward H, Jalan KN, Maitra TK, Agarwal SK, Mahalanabis D. Small intestinal nodular lymphoid hyperplasia in patient with giardiasis and normal serum immunoglobulins. *Gut*. 1983;24:120-6.