

Ruptured Interstitial Ectopic Pregnancy at 22 Weeks Gestation Diagnosed at Laparotomy: A Case Report

Dr. Mst. Moonmoon Begum^{1*}, Dr. Ferdousy Sultana², Dr. Hasina Banu³

¹Resident Surgeon, Obstetrics & Gynecology, Rangpur Medical college Hospital, Bangladesh

²Professor and Head of the Department of Obstetrics & Gynecology, Rangpur Medical college Hospital, Bangladesh

³IMO, Obstetrics & Gynecology, Rangpur Medical college Hospital, Bangladesh

***Corresponding author**
Dr. Moonmoon Begum

Article History

Received: 16.05.2018

Accepted: 26.05.2018

Published: 30.06.2018

DOI:

10.21276/sjmcr.2018.6.6.1



Abstract: Ectopic pregnancy in the interstitial part of the fallopian tubes is a rare event, associated with a high rate of complications due to delayed diagnosis. Rupture of such pregnancy often results in catastrophic hemorrhage. The differential diagnosis of acute abdominal pain in pregnancy is broad and can be complicated by atypical manifestations. Due to the lack of clinical understanding, angular or interstitial pregnancy does not appear to be recognized as a clinical entity and many cases are likely to go undiagnosed or incidentally diagnosed at laparotomy. This is a case report of a 18-year-old woman who was admitted in the obstetrics emergency department with 22 weeks pregnancy with severe lower abdominal pain. It was her first pregnancy and USG revealed intrauterine alive pregnancy of 22 weeks. At first she was managed conservatively but her condition was not improved. So, after consultation with general surgeon a decision for emergency exploratory laparotomy was done. Surprisingly it was a case of ruptured uterus and an about 22-weeks fetus with placenta and membranes lying freely in the peritoneal cavity. It was suggestive of a interstitial ectopic pregnancy which had grown upto 22 weeks, invaded the uterine cavity thus forming an angular ectopic, which ended up as the catastrophic event.

Keywords: Interstitial pregnancy, Angular pregnancy, Ectopic pregnancy, Gestational age

INTRODUCTION

An interstitial ectopic pregnancy develops in the uterine portion of the fallopian tube. Angular pregnancy originates in the interstitial portion of the fallopian tube and then grows into the adjacent uterine cavity. Thus an angular pregnancy is a continuation of an interstitial pregnancy. While interstitial pregnancies account for only 2-4% of all ectopic gestations [1-3] they cause a disproportionately high incidence of hemoperitoneum and shock, and the mortality rate is approximately twice that of other types of ectopic pregnancies [4]. There are reported cases of rupture at all gestational ages, including full term pregnancy with surgical delivery [4].

CASE REPORT

A 18-year-old primigravid woman was admitted in the obstetrics emergency department of Rangpur Medical College Hospital in June 2015. The patient had sudden abdominal pain several hours prior to admission without any history of spotting and

abdominal pain. Her menstrual periods were regular and her gestational age was 22+ weeks based on her last menstrual period and early ultrasonography. She was married for last one year and had no history of abortion or uterine curettage. At first, the patient was treated conservatively with intravenous fluids, antibiotics and painkiller. Other causes of acute abdomen were ruled out, but the condition of the patient was deteriorating such as severe abdominal pain, tachycardia and falling of blood pressure. So, the patient was subsequently shifted for emergency exploratory laparotomy. Peroperatively there was hemoperitoneum and an about 22 weeks dead fetus with placenta was lying freely in the peritoneal cavity and fundus of the uterus along with right lateral wall was badly ruptured. As the uterus could not be salvaged, total abdominal hysterectomy was done. She was shifted to the intensive care unit postoperatively. She required correction of her electrolyte imbalance and further blood transfusions during her recovery period. She was discharged on 12th postoperative day after complete recovery.

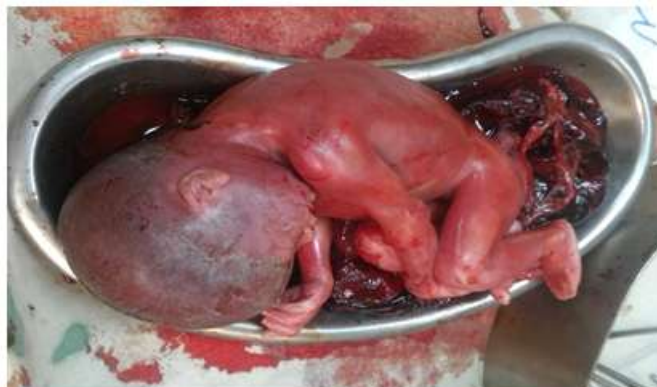

Fig-1(a): Dead fetus of about 22 weeks with placenta

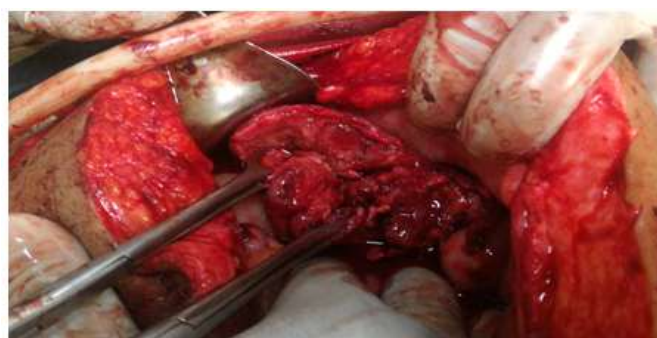

Fig-1(b): Rupture of fundus and lateral wall of the uterus

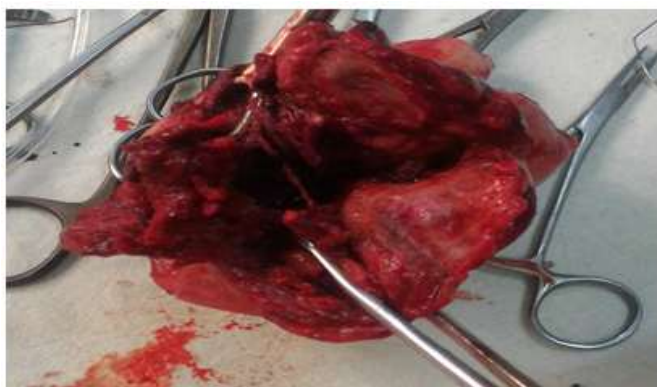

Fig-1(c): uterus after removal, it was so badly ruptured that could not be preserved.

DISCUSSION

Angular pregnancy was first defined in 1898 by the American obstetrician Howard Kelly as "implantation of the embryo just medial to the uterotubal junction, in the lateral angle of the uterine cavity" and medial to the round ligament [5]. In the literature, terms such as "cornual", "interstitial", and "angular" pregnancies are used incoherently. Some sources use "cornual" and "interstitial" synonymously, while others use "cornual" for gestations in bicornuate or septate uteri; others differentiate interstitial from angular pregnancy, while in practice, many physicians are unfamiliar with such classification [6].

In an interstitial ectopic pregnancy, the fertilized ovum implants in the proximal segment of the

fallopian tube covered by thin myometrium. Left undetected, such a pregnancy may develop till the early second trimester with the potential risk of catastrophic hemorrhage and greater maternal mortality risk than ampullary ectopic pregnancy [7]. The majority of ectopic pregnancies are tubal (95%), most commonly in the ampulla of the fallopian tube. Two to four percent of ectopic pregnancies are interstitial [7].

Risk factors associated with the higher incidence of interstitial ectopic pregnancy include congenital uterine anomalies, previous ectopic pregnancy, in vitro fertilization and ovulation induction, pelvic inflammatory disease, previous intrauterine procedures and intrauterine contraceptive devices [2].

Early diagnosis of interstitial ectopic pregnancy, in first trimester relies heavily on transvaginal ultrasound, which may be supplemented with a 3D-dimensional approach. Timor-Tritsch *et al.*, [8] established 3 sonographic criteria for the diagnosis

of interstitial pregnancy (Figure-2): (1) an empty uterus, (2) a chorionic sac separated and at least 1 cm from the lateral edge of the uterine cavity, and (3) a thin myometrial layer (< 5mm) surrounding the gestational sac.

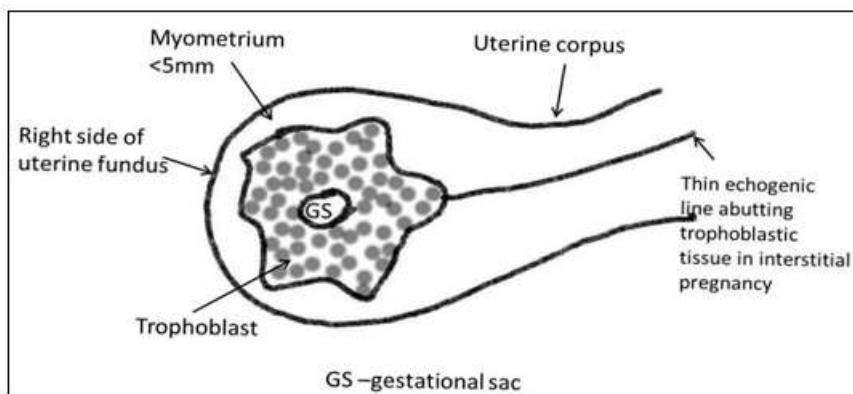


Fig-2: Diagram depicting the sonographic criteria for diagnosis of interstitial pregnancy in the first trimester. A gestational sac eccentrically located in the one side of the uterine fundus, surrounded by asymmetric thin myometrial layer (<5mm) and the interstitial line sign, which refers to an echogenic line that runs from the endometrial cavity to the cornu of the uterus abutting the gestational sac.

Though interstitial pregnancies are known to rupture earlier than 12 weeks of gestation [7], instances of interstitial pregnancy that advance to term, or near term, are not uncommon [9, 10].

We present a rare case of ruptured interstitial ectopic pregnancy diagnosed at 22 weeks gestation as it was not clearly determined by ultrasound.

Current management of interstitial ectopic pregnancy involves medical (methotrexate therapy) and surgical management. Surgical management is indicated in ruptured or advanced interstitial ectopic pregnancy [11]. Our case was treated by laparotomy as it was ruptured.

CONCLUSION

The diagnosis of interstitial ectopic pregnancy is challenging, particularly at an advanced stage due to equivocal ultrasound findings. So, it should be kept in mind that, an angular or interstitial pregnancy is rare, but it has catastrophic consequences including maternal mortality. Hence, in patient of early pregnancy with history of previous ectopic, a careful ultrasonography and color Doppler would have been useful in early detection and a fertility preserving conservative line of management in the form of Methotrexate therapy or Selective Uterine artery embolization could have been done.

REFERENCES

1. Bond AL, Grifo JA, Chervenak FA, Kramer EE, Harris MA. Term Nterstitial Pregnancy With Uterine Torsion: Sonographic, Pathologic, And
2. Clinical Findings. Obstetrics & Gynecology. 1989 May 1;73(5):857-9.
3. Maliha WE, Gonella P, Degnan EJ. Ruptured interstitial pregnancy presenting as an intrauterine pregnancy by ultrasound. Annals of emergency medicine. 1991 Aug 1;20(8):910-2.
4. Coady DJ, Snyder JR, Goldstein SR, Subramanyan BR. Ultrasound diagnosis of interstitial pregnancy. New York state journal of medicine. 1985 Nov;85(11):655.
5. Jafri SZ, Loginsky SJ, Selis JE, Bouffard JA. Sonographic detection of interstitial pregnancy. Journal of clinical ultrasound. 1987 May 1;15(4):253-7.
6. Tanaka Y, Mimura K, Kanagawa T, Kajimoto E, Takahashi K, Kakigano A, Fujita S, Kinugasa-Taniguchi Y, Endo M, Kimura T. Three-Dimensional Sonography in the Differential Diagnosis of Interstitial, Angular, and Intrauterine Pregnancies in a Septate Uterus. Journal of Ultrasound in Medicine. 2014 Nov 1;33(11):2031-5.
7. Arleo EK, DeFilippis EM. Cornual, interstitial, and angular pregnancies: clarifying the terms and a review of the literature. Clinical imaging. 2014 Nov 1;38(6):763-70.
8. Tulandi T, Al-Jaroudi D. Interstitial pregnancy: results generated from the Society of Reproductive Surgeons Registry. Obstetrics & Gynecology. 2004 Jan 1;103(1):47-50.
9. Timor-Tritsch IE, Monteagudo A, Matera C, Veit CR. Sonographic evolution of cornual pregnancies treated without surgery. Obstetrics and gynecology. 1992 Jun;79(6):1044-9.

9. Ng PH, NorAzlin MI, Nasri NI. Term interstitial pregnancy with uterine conservation. *International Journal of Gynecology & Obstetrics*. 2007 Dec 1;99(3):251.
10. Scarella A, Marquez R, Schilling H, Palomino A. Antenatal diagnosis of a third trimester interstitial pregnancy: a case report. *Journal of Obstetrics and Gynaecology Research*. 2012 Mar 1;38(3):570-3.
11. MacRae R, Olowu O, Rizzuto MI, Odejinmi F. Diagnosis and laparoscopic management of 11 consecutive cases of cornual ectopic pregnancy. *Archives of gynecology and obstetrics*. 2009 Jul 1;280(1):59.