

**Strongyloides stercoralis Infection in a 32 Years Male Patient**

Dr. S Srikanth\*

Associate Professor, Department of Pathology, Prathima Institute of Medical Sciences, Nagunur, Karimnagar, Telangana, India.

**\*Corresponding author**

Dr. S Srikanth

**Article History**

Received: 05.06.2018

Accepted: 14.06.2018

Published: 30.06.2018

**DOI:**

10.21276/sjmcr.2018.6.6.5



**Abstract:** *Strongyloides Stercoralis* is a nematode and infection from it is common in Sub-Saharan and South East Asia continent. It is mostly asymptomatic but if it presents, then is usually seen with vague gastrointestinal complaints. Small bowel obstruction is a poorly recognized and possibly underreported complication. We hereby present a case of partial small bowel obstruction from *S. Stercoralis*. A 32 year old man presented with one year history of post prandial nausea, abdominal bloating and bilious vomiting along with significant weight loss. He presented to different hospitals and was treated for his symptoms, but a definite diagnosis could not be made. Biopsy was done and sent for histopathological examination and finally it was diagnosed as *Strongyloides Stercoralis*.

**Keywords:** *Strongyloides Stercoralis*, obstruction, intestine.

**INTRODUCTION**

*S. Stercoralis* infection is normally asymptomatic, but may manifest with symptoms of nausea, vomiting, anorexia, weight loss, abdominal discomfort, flatulence and diarrhea. Unusual presentation includes intestinal obstruction and GI bleed. Loffler syndrome is descriptive for pulmonary symptoms like cough and wheezing. Heavy infestation of lungs may lead to dyspnea, pleuritic pain and hemoptysis. Larva currens (“racing larva”) is an itchy, cutaneous condition caused by infections with *Strongyloides Stercoralis*. It is caused by the intradermal migration of *Strongyloides*.

**CASE REPORT**

A 32 years male patient came to surgery out patient department with complains of pain abdomen, vomitings and history of weight loss from past one year. All routine investigations were done and all were normal. Ultrasound and CT scan were also found to be normal. Due to pain abdomen continuously, small bowel

biopsy was done and sent for biopsy to rule out any underlying cause. All the tissue was submitted and observed under microscope and it was found to be *S stercoralis*. Section showed plenty of larval forms of *S stercoralis* along with focal eosinophilia [Figure 1 &2] and it was confirmed as intestinal obstruction due to *S stercoralis* infection.

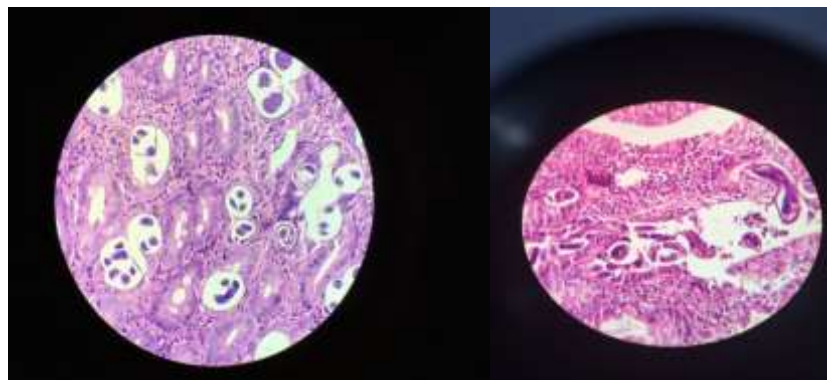


Fig-1&2: showed plenty of larval forms of *S stercoralis* along with focal eosinophilia

**DISCUSSION**

*Strongyloides* infects 30 to 100 million people worldwide. It is endemic in the southeastern United States, South America. The worms live in the soil and infect humans when larvae penetrate the skin.

*S stercoralis* is a parasitic human nematode, endemic in South-Eastern USA, South Asia, Latin America and sub-Saharan Africa. It is estimated over 100 million humans are infected with *S stercoralis* [1]. The lifecycle of the nematode is complex; infection is initially transdermal with haematogenous

dissemination of filariform larvae to the lung where the parasite gains access to the tracheobronchial tree through the alveolar sacs. The larvae migrate up the tracheobronchial tree, gaining access to the GI tract before laying eggs in the duodenum and jejunum, which hatch into rhabditiform larvae capable of autoinfection of the host through the intestinal mucosa or perianal skin [2]. Infection may present with vague abdominal symptoms including generalised abdominal pain, diarrhoea, constipation, borborygmus and flatulence, although 50% of infections are asymptomatic. Malabsorption and an eosinophilic pneumonitis may occur in severe cases [3].

Immunity to *S. stercoralis* is conferred through humoral, complement and granulocytic responses [4]. Immunocompromise can lead to a hyperinfection syndrome and disseminated disease, where the presence of the parasites extend outside of the traditional lifecycle (ie, in organs other than the skin, GI tract or lungs)- Patients with haematological malignancy and those treated with corticosteroids have also been identified as having a higher risk of *S. stercoralis* hyperinfection syndrome. Buonfrate *et al.* [4] reviewed 244 cases for risk factors associated with *S. stercoralis* hyperinfection syndrome and found 67% of patients were being treated with corticosteroids.

A number of cases have reported *S. stercoralis* hyperinfection in patients with multiple myeloma undergoing chemotherapy and Seet *et al.* reviewed a series of five cases where *S. stercoralis* hyperinfection presented in patients with primary or functional hypo- $\gamma$ -globulinaemia. Interestingly, subsequent tests (after the resolution of *S. stercoralis* infection) also revealed HTLV-1 infection in the patient described here. Buonfrate *et al.* [4] found HTLV-1 coinfection in 10% of the 244 cases presenting with hyperinfection syndrome. It is hypothesised that HTLV-1 driven overproduction of interferon  $\gamma$  suppresses the interleukin (IL)-4, IL-5 and IgE responses necessary to control chronic helminth infection.

Cruz *et al.* recently reviewed the literature reporting cases of duodenal obstruction secondary to *S. stercoralis* infection. Since 1970, eight cases have been reported, six of which had no associated haematological disease, one had concurrent HTLV-1 infection and another poorly differentiated small bowel lymphoma. None had concurrent monoclonal  $\gamma$ -globinopathy of unknown significance or multiple myeloma. Histopathological studies of samples of gastric and duodenum of immunocompromised patients demonstrating *S. stercoralis* infection show prominent eosinophilia, and evidence of subacute and/or chronic inflammatory changes, similar to the histology of the peritoneal biopsies seen in this case.

*Strongyloides stercoralis* infection and hyperinfection syndrome are rare in the UK but should be considered as a differential diagnosis in patients who have lived in or travelled to endemic areas and present with non-specific abdominal symptoms.

Haematological malignancy, corticosteroid use, human T-lymphotropic virus type-1 and/or HIV-1 infection are risk factors for *S. stercoralis* hyperinfection syndrome.

The treatment of choice for *S. stercoralis* hyperinfection is ivermectin. However, where ivermectin is unavailable, benzimidazole-based agents including mebendazole and thiabendazole may also be used.

#### REFERENCES

1. Burke M. Acute intestinal obstruction: diagnosis and management. *Hosp Med* 2002;63:104–7.
2. Ganesh S, Cruz RJ., Jr Strongyloidiasis: a multifaceted disease. *GastroenterolHepatol (N Y)*2011;7:194– 196.
3. Segarra-Newnham M. Manifestations, diagnosis, and treatment of Strongyloidesstercoralis infection. *Ann Pharmacother* 2007;41:1992–2001.
4. Buonfrate D, Requena-Mendez A, Angheben A, et al. Severe Strongyloidiasis: a systematic review of case reports. *BMC Infect Dis* 2013;13:78.